

## Kaposi Sarcoma of the Nasal Cavity: A Rare Presentation

Adamu Abubakar <sup>1</sup>, Abba Bukar Z<sup>2</sup>, Ahmed Mohammed N<sup>3</sup>, Amina Muhammad A<sup>1</sup>, Aliyu Mohammad Kodiya<sup>1</sup>

### ABSTRACT

**Background:** Kaposi sarcoma (KS) is an uncommon vascular neoplasm that commonly involves the skin of the upper and lower extremity and to a lesser extent, mucosa of the different anatomical sites of the body. It rarely occurs in the head and neck mucosa, the most common site being the oral cavity. Nasal mucosal involvement is extremely rare. To the best of our knowledge, only nine cases of KS of the nasal cavity were reported in the English literature. We present a rare differential to be considered when dealing with patients with nasal mass. **Case summary:** A 47 year old Nigerian woman presented with 3 years history of recurrent epistaxis, a right nasal mass, progressive right nasal obstruction, rhinorrhoea and anosmia. She is diabetic and hypertensive. Examination revealed a polypoid mass occupying the whole of the right cavity with associated contact bleeding. **Conclusion:** Nasal KS is a rare malignancy that involved the nasal mucosa. To our knowledge, only nine cases of primary nasal KS were reported in the literature of which only a few were not associated with AIDS. Though rare, it should be entertained as one of the differential diagnoses of nasal masses in adults even in those with HIV-negative status We present the fifth case of primary nasal KS not associated with AID

**Keywords:** Kaposi sarcoma, nasal cavity, acquired immunodeficiency syndrome

<sup>1</sup>Department of Ear, Nose and Throat Surgery  
University of Maiduguri Teaching Hospital,  
Maiduguri Borno State.

<sup>2</sup>Department of Histopathology, University of  
Maiduguri Teaching Hospital, Maiduguri Borno  
State.

<sup>3</sup>Department of Anaesthesiology, University of  
Maiduguri Teaching Hospital, Maiduguri Borno  
State.

### Corresponding Author:

Adamu Abubakar, Department of ENT Surgery,  
University of Maiduguri Teaching Hospital, PMB  
1414, Maiduguri, Borno State Nigeria. Email:  
adamuabubakar411@gmail.com

Contact number: +2348036338889

Submitted: Dec 2021

Accepted: Dec 2021

Published Online: Feb 2022

### Introduction

Kaposi sarcoma (KS) was first reported in 1872 by Moritz Kaposi, an Austrian dermatologist, who described it as an "idiopathic multiple pigmented sarcomas of the skin."<sup>1</sup> Kaposi sarcoma is a low grade angioproliferative endothelial tumour associated with human herpes virus 8 (HHV-8), also called KS-associated herpes virus. Between 4-15% of the healthy population may be seropositive for HHV-8; however, KS is seen only in individuals that are immunocompromised.<sup>2</sup> With AIDS epidemic, Kaposi sarcoma was recognized as the most commonly encountered malignancy in AIDS patients, and hence it became an AIDS-defining condition.<sup>3</sup> Kaposi sarcoma most commonly occurs on the skin and mucosal surfaces however, it can involve virtually any organ of the body<sup>4</sup>. With the onset of AIDS, there has been an increased incidence of KS involving the head and neck, as high as 66% involvement of the head and neck sites was reported<sup>4,5</sup>. Head and neck KS is rarely encountered in HIV-negative or non-immunosuppressed individuals.<sup>6</sup> Primary nasal mucosal KS is exceedingly rare, with only some cases previously reported in the English literature; only very few were not AIDS-associated.<sup>7,8,9</sup>

### Access this article online

Quick Response Code



website: [www.bornomedicaljournal.com](http://www.bornomedicaljournal.com)

DOI: 10.31173/bomj.bomj\_2138\_19



**Case presentation**

A 47 year old woman presented with a 3 years history of recurrent epistaxis, a right nasal mass, progressive right nasal obstruction, rhinorrhoea and anosmia. She was a known diabetic as well as hypertensive. However, she has no risk factors for HIV and is not on any immunosuppressive medication. Physical examination revealed a polypoid mass occupying the whole of the right nasal cavity with associated contact bleeding (fig.1), there was no palpable lymph node or cutaneous lesions. Relevant investigations were requested but the patient defaulted and just to be rushed to the accident and emergency unit of the hospital later with severe epistaxis for which she was resuscitated and transfused. A computerized tomographic scan showed a tumour occupying the entire right nasal cavity displacing the nasal septum to the contralateral side. There was osteolytic destruction of the medial wall and roof of the maxillary antrum with extension into the orbit ipsilateral ethmoidal sinuses and nasopharynx (fig. 2). She had endoscopic examination and biopsy under local anaesthesia and histology confirmed. HIV screening was negative, Chest X-ray and abdominal ultrasound scan were normal, fasting blood sugar was 5.5mmol/l, electrolytes were within normal limit. She had endoscopic excision. Intraoperative findings revealed a right intranasal polypoid mass that is friable with contact bleeding, arising from the lateral wall of the nasal cavity. The mass filled the right

nasal cavity pushing the septum to the contralateral side. The Mass was excised endoscopically. Histology showed a tissue partly covered with respiratory epithelium, displaying malignant mesenchymal neoplasm composed of plump spindle shape cells forming slit-like spaces containing red blood cells in keeping with Kaposi sarcoma (Fig. 3). The patient had chemotherapy 3 weeks after the surgery using I.V Doxorubicin at 60mg/m<sup>2</sup> and was repeated every 21 days for 4 cycles. A patient has been on regular follow-up with good local control after one year of completing the chemotherapy.

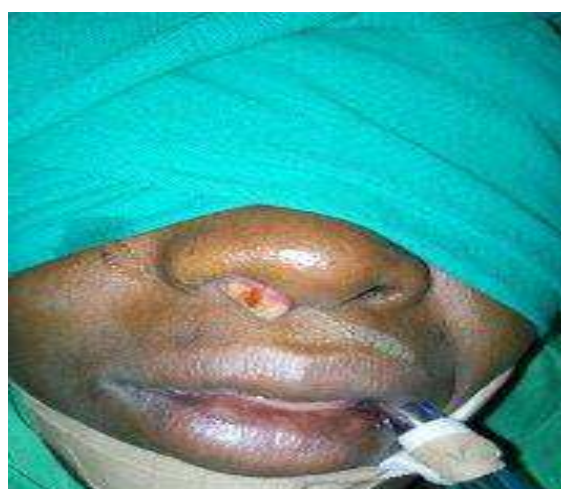

Figure 1: Tumour mass in the right nasal cavity projecting outward

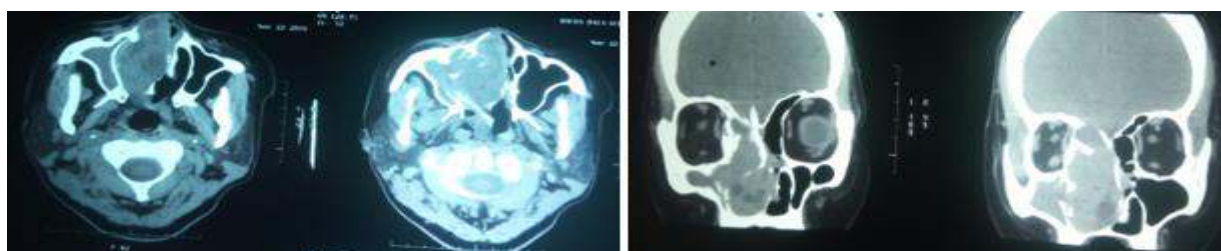


Figure 2 Axial and coronal CT showing tumour occupying the right nasal cavity causing erosion of the nasal septum and medial wall of the maxillary antrum with extension into the maxillary and ethmoidal sinuses.



A, section shows tissue partly covered by respiratory type epithelium (white arrow) and malignant mesenchymal neoplasm composed of plump spindle shape cells (black arrow), (H and E X100).

B, section shows tissue partly covered by respiratory type epithelium (white arrow) and malignant mesenchymal neoplasm composed of plump spindle shape cells (black arrow), (H and E X100).

C, Section shows malignant mesenchymal neoplasm with extravasated red blood cells within a slit-like spaces bounded by spindle cells (indicated by two white arrows).



## Discussion

Kaposi sarcoma is an opportunistic disease and one of the AIDS-defining illnesses that frequently occurs in HIV-positive patients. Oral, craniofacial and cutaneous manifestations of KS are seen in up to 95% of patients with AIDS-related KS, and only < 5% of KS cases are seen in individuals with no AIDS.<sup>10,11</sup> About two-thirds (66%) of mucosal KS involved the head and neck and are most frequently seen in the oropharynx and oral cavity<sup>5</sup>. Other sites that may be involved include the larynx, sinuses, major salivary gland and jaw bones<sup>5,12</sup>. Only a few reported cases of Kaposi's sarcoma involved the nasal mucosa.<sup>8,13</sup> Mouden et al<sup>8</sup> reported the case of a 56-year-old female of Mediterranean descent with primary nasal Kaposi sarcoma who was treated with chemotherapy and was disease-free at 1 year follow up, prior to his report only eight cases of Kaposi sarcoma in the nasal mucosa were reported.

We reported a case of KS of the right nasal cavity in a 47 year old known diabetic, who is HIV negative. Patients with nasal KS usually present with a history of chronic sinus congestion, nasal obstruction and occasional minor epistaxis. In this report, the patient presented initially with a history of recurrent epistaxis, progressive right nasal blockage, right nasal mass and anosmia and later with severe epistaxis. Epistaxis is prominent in this presentation probably due to the long-standing nature of the disease, its vascularity and the coexisting chronic conditions that may predispose to atherosclerosis.

Human herpes virus 8 (HHV8) play a consistent role in the aetiology of KS and is found in nearly all clinicopathological setting of the disease.<sup>14</sup> However, KS has been associated with other potential aetiological factors including irradiation, HIV, corticosteroid therapy, immunosuppressive therapy for SLE, after kidney transplant, for a haematological disorder, asthma, ulcerative colitis and rheumatic disease<sup>6,15,16</sup>. This index patient is HIV negative, not on any immunosuppressive therapy and has no history of irradiation. The only co-morbid conditions were diabetes mellitus and hypertension.

The treatment of KS depends on the form of the disease, site of the lesion and its extent, the immunological status and the general medical status of the patient<sup>7</sup>. Local excision, radiation therapy and chemotherapy may be used either combined or as a single modality. Surgery may be performed for

symptomatic lesions such as those causing bleeding and ulcerative dermatitis. In selected immunocompetent individuals, limited excision alone can be curative<sup>7</sup>. Chen et al<sup>6</sup> used local excision combined with low-dose radiation therapy (3000 cGy) to treat a patient with iatrogenic nasal KS associated with immunosuppressant therapy for SLE and reported no recurrence during a four-year follow-up. Venizelos et al<sup>7</sup> reported a left nasal KS treated by excision alone and the patient had no recurrence four years after the treatment. Thariat et al<sup>5</sup> reported two patients who had bleomycin or caelyx (liposomal doxorubicin) following surgery and are disease-free at 71 and 54 months of follow up respectively. This index patient had surgery followed by 4 cycles of chemotherapy using doxorubicin and remained in good health after one year of follow-up.

## Conclusion

Kaposi sarcoma can rarely occur in the nasal cavity even in HIV-negative individuals as shown from this report. Although rare, it should be considered as part of the differential diagnosis of nasal masses even in HIV-negative individuals. We present the fifth case of nasal Kaposi sarcoma not associated with AIDS.

## References

1. Kaposi M. Idiopathic multiple pigmented sarcoma of the skin. Arch Dermatol Syphil. 1872; 4:265-73.
2. Araujo BC, Baptista SV, Mascarenhas L, Barros E. Maxillary Sinus Kaposi Sarcoma: Case Report in an HIV-Negative Patient with Thymoma, 2017;1-3.
3. Safai B, Diaz B, Schwartz J. Malignant neoplasms associated with human immunodeficiency virus infection. CA Cancer J Clin 1992; 42:74-95.
4. Huang H, Deng YY, Le XH, Lu PX. Primary intraosseous Kaposi's sarcoma of the maxilla in AIDS: a case report. Quant Imaging Med Surg 2013;3(6):334-338.
5. Thariat J, Kirova Y, Sio T, Choussy O, Vees H, Schick U, et al. Mucosal Kaposi sarcoma, a rare cancer network study. Rare tumours 2012;4: e49: 155-161.
6. Bottler t, kuttengerJ, Hardt N, Ochen HP, Balstenperger M. Non-HIV-associated Kaposi sarcoma of the tongue. Case report and review



- of literature. *Int J Oral Maxillofac Surg.* 2007; 36:1218-1220.
7. Chen KH, Chen TD, Chen CW, Lee L. Iatrogenic Kaposi's sarcoma in nasal cavity: a case report. *World Journal of Surgical Oncology* 2014 12:172.
  8. Venizelos I, Andreadis C, Tatsiou Z: Primary Kaposi's sarcoma of the nasal cavity not associated with AIDS. *Eur Arch Otorhinolaryngol* 2008; 265:717-720.
  9. Mouden K, Khmou M, Loughmari S, Semmar A, El Kacemi H, El Khannoussi B et al. Primary Kaposi's sarcoma of the nasal cavity: a case report and review of the literature. *Clin Sarcoma Res* 2016; 6(4):1-5.
  10. Ramírez-Amador V, Anaya-Saavedra G, Martínez-Mata G. Kaposi's sarcoma of the head and neck: a review. *Oral Oncol* 2010; 46:135-45.
  11. Patrikidou A, Vahtsevanos K, Charalambidou M, Valeri RM, Xirou P, Antoniadis K. Non-AIDS Kaposi's sarcoma in the head and neck area. *Head Neck.* 2009; 31:260-8.
  12. Agaimy A, Mueller SK, Harrer T, Bauer S, Thompon LDR. Head and Neck Kaposi sarcoma: Clinicopathological analysis of 11 cases. *Head and Neck Pathol* 2018;12, 511-516.
  13. Venizelos Ioannis, Andreadis Charalambos. Zoi Tatsiou "Primary Kaposi's sarcoma of the nasal cavity not associated with AIDS". *Eur Arch Otorhinolaryngol.* 2008; 265:717-20.
  14. Szajerka T, Jablecki J. Kaposi's sarcoma revisited. *AIDS Rev.* 2007; 9:230-6.
  15. Rachadi H, Zemmez Y, Znati K, Ismaili N, Hassam B. External ear nodule revealing a disseminated Kaposi disease. *Dermatol Online J.* 2016;22(8).
  16. De Pasquale R, Nasca MR, Micali G. Post irradiation primary Kaposi's sarcoma of the head and neck. *J Am Acad Dermatol.* 1999; 40:312-4.

---

**Cite this Article as:** Adamu Abubakar. Abba Bukar Z. Ahmed Mohammed N. Amina Muhammad A. Aliyu Mohammad K. Kaposi sarcoma of the nasal cavity: a rare presentation. *Bo Med J* 2022;19(1):69-72 **Source of Support:** Nil, **Conflict of Interest:** None declared

---

