

Foreign Body in the Throat: Any Trend Change?

Stephen Agbomhekhe Ogah

ABSTRACT

Background: Throat foreign bodies are surgical emergencies in both children and adults all over the world. Some patients may present with no obvious symptoms and for those that have symptoms, their symptoms may suggest which passage is involved. Children below the age of 10 years are more affected than adults. Smooth objects like coins and seeds may pass through the gastrointestinal tract with little or no problem in about 30% of cases and so, such patients should be placed under close observation in the wards. **Aims/Objectives:** To determine the types, site of impaction and method of removal of such foreign bodies among patients seen in our health facility. **Methodology:** This is a 3-year retrospective study conducted at the ENT Unit of the Department of Surgery Federal Medical Centre Lokoja, North Central Nigeria. From the hospital Medical Records, a total of 82 patients were managed for foreign body in the throat. However, folders for seven patients could not be traced, five folders had incomplete information in them, and the remaining 70 folders were included in the study. Data about their age, sex, presentation, duration, type, site of impaction, method of removal were extracted, studied and analysed. Results were presented in text, figure and table format. **Results:** A total of 70 patients were studied, 36 (51.4%) were males and 34 (48.6%) were females. The male to female ratio was 1.06:1, mean age was 17.14 years \pm 8.36 standard deviation and the most frequent age group involved was of 21-30 years with 26 (37.1 %) patients. Commonest site of impaction was the oropharynx (74.3%) followed by the upper oesophagus (11.4%). The most common foreign body was fishbone (57.2%) followed by denture (8.6%).

Keywords: Throat, foreign, bodies, analysis.

Department of Surgery, Federal Medical Centre P.M.B. 1001, Lokoja, Kogi State, Nigeria.

Corresponding Author

Department of Surgery, Federal Medical Centre
P.M.B. 1001, Lokoja, Kogi State, Nigeria.
Email: stephenogah@yahoo.com
Mobile: +2348075224222

Introduction

Foreign bodies are objects that are not part of the normal anatomy of the human body that are inserted into any of the craniofacial orifices. Throat foreign bodies are surgical emergencies encountered in both children and adults.¹ Symptoms will suggest whether the object is in the airway or food pathway and this can be confirmed by ordering appropriate radiological investigations.² About 30% of smooth objects like coins and seeds will pass down the gastrointestinal tract to be expelled in stool in those children between the age of 6 months to 3 years. So, such patients should be closely observed provided they are asymptomatic.³ However, large, sharp and pointed objects had to be

Access this article online

Quick Response Code



website: www.bornomedicaljournal.com

DOI: 10.31173/bomj.bomj_109_16



urgently removed as they can obstruct or migrate with more dangerous consequences.⁴ Throat foreign bodies may be animate or inanimate, organic or inorganic, biological or non-biological and metallic or non-metallic.⁴ They can have varying shapes and sizes that influence the choice of their mode of removal.⁵

It is a commonly encountered problem in the practice of Otolaryngology irrespective of gender and geographical location. It is however more common in children, the elderly, those patients with psychiatric disorders, patient with mental retardation and alcoholics than the general population⁶. The peak age for children is said to range from 6 months to 6 years and the common sites include the tonsil beds, valleculae and regions of oesophageal constrictions.⁷

In children, foreign bodies such as coins, toys, keys, beads, batteries, bean seed, eraser and crayon have been reported whereas in adults, fishbone, denture, meat parts, nails, safety pins, hair clips were also reported.⁸

The prevalence varied greatly with the type of foreign body and among the children coins were found to be the commonest foreign bodies in the oesophagus.⁹⁻¹¹

Most will present as emergency in the Accident and Emergency Department of the hospital with the history of difficulty in breathing, inability to swallow saliva or food and pain.¹¹

Those that may present in the outpatient clinic usually have none of these life-threatening symptoms.

Aims/Objectives: To determine the types, site of impaction and method of removal of such foreign bodies among patients seen in our health facility.

Materials and Methods

This is a 3-year retrospective study conducted at the ENT Unit of the Department of Surgery Federal Medical Centre Lokoja, North Central Nigeria. From the hospital Medical Records a total of 82 patients were managed for foreign body in the throat. However, folders for seven patients could not be traced, five folders were excluded due to incomplete information and the remaining 70 folders were included in the study. Data about their age, sex, presentation, duration, type, site of impaction, method of removal were extracted, studied and analyzed. Results obtained were presented in text, figure and table format.

Results

A total of 70 patients were studied, 36(51.4%) were males while females were 34(48.6%). The male to female ratio was 1.06:1. Their ages range from 1 to 60years, mean age was 17.14years \pm 8.36 standard deviation. The most frequent age group was of 21-30years with 26(37.1 %) patients (Figure1). Fishbone (57.2%) was the commonest foreign body found in this study followed by denture and most of them were found in the oropharynx (74.3%) and upper oesophagus (11.4%) (tables 1 and 2). Thirty patients (45.7%) had their foreign bodies removed in the clinic, 25(35.7%) were removed in the theatre, 10(14.3%) were passed in stool after an average period of about 2-3days observation and 3(4.3%) patients foreign bodies were not found. Most of the fishbone were found in the oropharynx 46(65.7%) at the tonsil beds, base of the tongue and the valleculae. The majority of them were removed in the clinic. Others removed in the theatre were found in the laryngopharynx and the oesophagus (figure2).



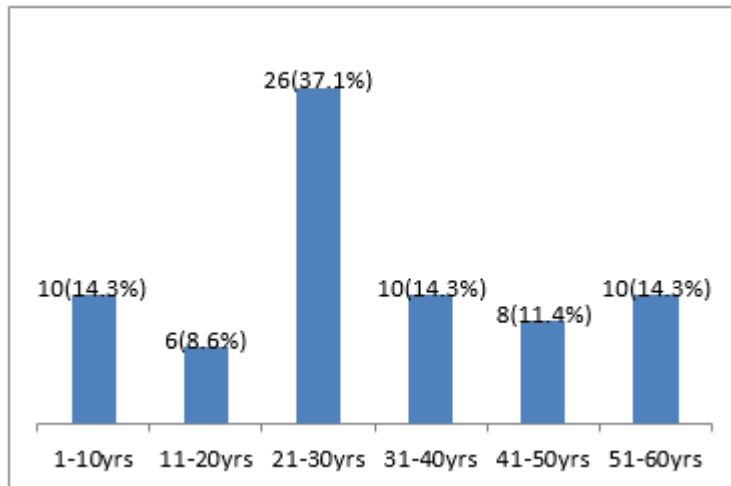


Figure 1: Age distribution of patients with throat foreign bodies.

Table 1: Types of throat foreign bodies found

Type of foreign body	Number (%)
Fishbone	40 (57.2)
Denture	6 (8.6)
Buttons	5 (7.1)
Toys	4 (5.7)
Nails	3 (4.3)
Meat	3 (4.3)
Office pins	2 (2.9)
Beads	2 (2.9)
Plastic part	1 (1.4)
Needle	1 (1.4)
Coin	1 (1.4)
Kola nuts	1 (1.4)
Fishhook	1 (1.4)
Total	70 (100.0)

Table 2: Site of Impaction of throat foreign bodies

Sites of impaction	Frequency (%)
Pharynx	46 (65.7)
Proximal Oesophagus	8 (11.4)
Mid Oesophagus	2 (2.9)
Distal Oesophagus	1 (1.4)
Passed in faeces	10 (14.3)
Not seen	3 (4.3)
Total	70 (100.0)



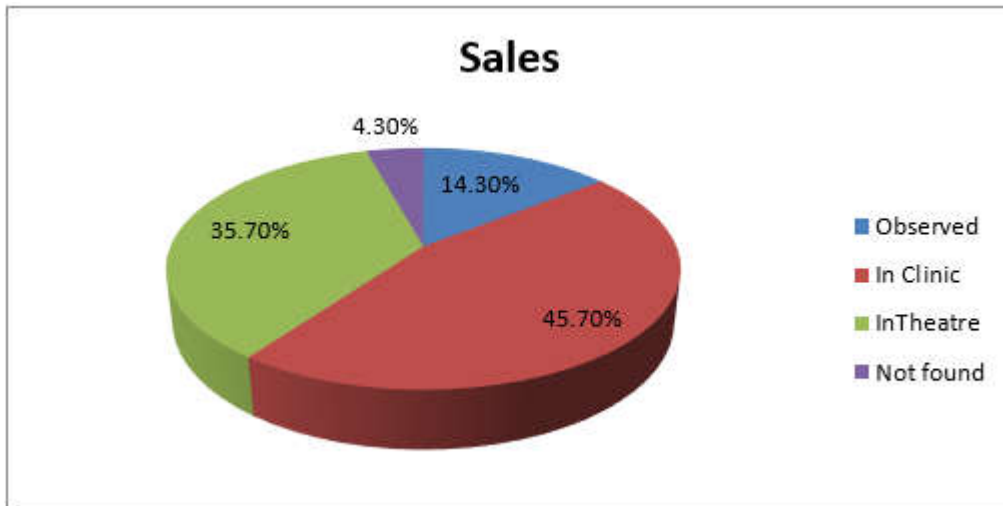


Figure 2: How and where throat foreign bodies were removed

Discussion

Different types of throat foreign bodies have been reported in the literature with their potential danger if not given the right attention.¹² Airway foreign bodies are mostly dangerous due to their association with airway obstruction, sudden death, aspiration pneumonitis, atelectasis, lung abscesses and damage.¹² Sharp and pointed object has the ability to cause perforation of the gastrointestinal tract, haemorrhage and possible migration to other sites where it causes further injuries. For these reasons, urgent removal is usually advocated whenever encountered in clinical practice. However, about 30% smooth or blunt foreign bodies can pass through the gastrointestinal tract to be expelled in stool without harming the patient.¹³ In this study throat foreign bodies were found mostly in the age group of 21-30year (37.1%) and this is in contrast to most studies that had reported a much lower age range of 1-10years.¹⁴

The most common foreign body in this study is fishbone and again in contrast to most studies that had reported coins as the most common oesophageal foreign body in the paediatric age group.¹⁵⁻¹⁷ I am not surprised because coins have disappeared from

circulation as a currency in the Nigerian market for over two decades now without any obvious reasons and so not readily available in our various homes. Again, Lokoja is the confluence city of the Benue and Niger rivers and fishing activity is both professional as well as a hobby in this city.

Fish is therefore a major food ingredient and a common delicacy that is taken regularly among the indigenous population. The commonest site of impaction of these foreign bodies in this study was in the oropharynx 46(65.7%) around the tonsillar beds, base of the tongue and the valeculae.


This may be due largely to the nature of the foreign bodies. Fish bones are flexible and pointed by their nature. They easily get trapped in some of these areas during swallowing. The proximal oesophagus was the second most common site of foreign body impaction in this study and this is in agreement with findings by other researchers.¹⁸⁻²⁰ Most of the foreign bodies were removed in the clinic (45.7%) with instrument like artery or Magill forceps as they were located in the oropharynx and for those that were removed in the theatre (35.7%) rigid oesophagoscopy was the method of choice.

Conclusion

Fish bone foreign bodies are common in medical practice and the majority of them can be removed in a clinic setting using a good headlight and simple instrument. Rigid oesophagoscopy is usually reserved for other throat foreign bodies that are located in the oesophagus. Limitations of this study include the fact that it is a Federal Medical Centre hospital-based study as not all those who had throat foreign bodies come to our hospital and the fact that more years were not covered.

References

1. Louie JP, Alpern ER, Windreich RM. Witnessed and unwitnessed esophageal foreign bodies in children. *Pediatr Emerg Care* 2005; 21:582
2. Sewagegnyeshiwas, Damteshemeli. Patterns of foreign body in the aerodigestive tract of the pediatric patients in TikurAnbesa Hospital. *Ethiopian Journal of Pediatrics and Child Health* 2010; 6(6):4-13.
3. Haidary A, Leider J S, Silbergleit R. Unsuspected swallowing of a partial denture. *Am J Neuroradiol.* 2007; 28:1734-5.
4. Ogah SA, Olatoke F, Okomanyi A and Igbobu B. Fishhook and line impaction in the Esophagus: An unusual and interesting foreign body. *IOSR Journal of Dental and Medical Sciences.* 2014; 6:63-64.
5. Smith MT, Wong RKH. Esophageal foreign bodies: types and technique for removal. *Curr Treat Options Gastroenterol* 2006; 9: 75-84.
6. Uyemura MC. Foreign body ingestion in children. *Am Fam Physician* 2005; 72:287.
7. Wyllie R. Foreign bodies in the gastrointestinal tract. *Curr Opin Pediatr* 2006; 18:563.
8. Lee TH, Kang YW, Kim HJ, Kim SM, Im EH, Huh KC, et al. Foreign objects in Korean prisoners. *Korean Int Med J* 2007; 22:275-8.
9. Shivakumar AM, Naik AS, Prashanth KB, Yogesh BS, Hongal GF. Foreign body in upper digestive tract. *Indian J Pediatr* 2004; 71:689.
10. Tadesse A, Feyo A. Management of Ingested Foreign Bodies in Paediatric Patients: An Experience from a Tertiary Hospital in Ethiopia. *East Cent Afr J Surg.* 2014; 19:11-16.
11. Iseh KR, Oyedepo OB and Aliyu D. Pharyngo-oesophageal Foreign Bodies: Implications for Health Care Services in Nigeria. *Annals of African Medicine.* 2006; 5:52-55.
12. Kay M, Wyllie R. Pediatric foreign bodies and their management. *Curr Gastroenterol Rep* 2005; 7:212.
13. Sharieff GQ, Brousseau TJ, Bradshaw JA, Shad JA. Acute esophageal coin ingestions: is immediate removal necessary? *Pediatr Radiol* 2003; 33:859.
14. Asif M, Haroon T, Khan Z, Muhammad R, Malik S, Khan F. Foreign body esophagus: types and site of impaction. *Gomal J Med Sci* 2013; 11:163-6.
15. Awe JAA. Overview of the management of swallowed gastrointestinal tract foreign body. *Global Advanced Research Journal of Microbiology.* 2013; 2(6):99-106.
16. Ekim H. Management of esophageal foreign bodies: a report on 26 patients and literature review. *Eastern J Med* 2010; 15:21-5.
17. A-Kader HH. Foreign body ingestion: children like to put objects in their mouth. *World J Pediatr.* 2006; 10:301-310.
18. Yardeni D, Yardeni H, Coran AG, Golladay ES. Severe esophageal damage due to



- button battery ingestion: can it be prevented? *Pediatr Surg Int* 2004; 20:496.
19. Russell RT. Tracheo esophageal fistula following button battery ingestion: successful nonoperative management. *J Pediatr Surg* 2013; 48(2):441-4.
20. Lee TH, Kang YW, Kim HJ, Kim SM, Im EH, Huh KC, et al. Foreign objects in Korean prisoners. *Korean. Int Med J.* 2007; 22:275-278.

Cite this Article as: Stephen Agbomhekhe Ogah. Foreign Body in the Throat: Any Trend Change? *Bo Med J* 2019;16(1): **Source of Support:** Nil, **Conflict of Interest:** None declared

